

HISTOMORPHOLOGICAL EFFECTS OF AQUEOUS LEAF EXTRACT OF PHYLLANTHUS AMARUS SHUM AND THONN ON THE TESTIS OF ADULT WISTAR RATS

J. E. Ataman¹ and M. Ikediashi²

Department of Anatomy, School of Basic Medical Sciences, College of Medical Sciences, University of Benin, Benin-City, Nigeria.

ABSTRACT: *The study was conducted for twelve weeks to investigate the effects of 250 mg/kg body weight of ethanolic leaf-extract of Phyllanthus amarus on the morphology and sperm parameters of the testis. Twenty (20) adult male Wistar rats were categorized into two groups of ten rats each (n=10) with A (control), B (to assess the effects of the extract on testicular morphology and sperm parameters). The body and organ weight of the experimental animals were noted before and at the end of the experiment and the significance of data was analyzed using student t- test (p<0.05). The results revealed no significant difference (p>0.05) in the body and organ weight between the experimental groups and the control. There were significant difference (p<0.05) in the total sperm count, sperm motility and viability in the treatment group compared to control with obvious decrease in all the parameters. The rats treated with ethanolic extract of P.amarus showed various degrees of testicular degeneration compared to the control demonstrating seminiferous tubular lumen with scanty spermatozoa, distorted seminiferous epithelium and arrested differentiation and progression of germ cells into the lumen. The epididymis also showed scanty and moderate clusters of spermatozoa in the lumen with thickened epithelial lining. The findings are consistent with anti-fertility remarks on the effects of P. amarus on testicular morphology and functions.*

KEY WORDS: P.amarus, Testis, Morphology, Sperm Parameters, Wistar rats

INTRODUCTION

Some agents have been reported to have deleterious effects in the testes and epididymis and may cause reduction in sperm concentration and the production of abnormal gametes (Sundaram and Witorsh., 1995). This may be due to their adverse role on the functions of the Leydig cells affecting testosterone production (Mooradian *et al.*, 1987), or by direct assault on the morphological picture of the testis and thus interfering with spermatogenesis through disruption of the seminiferous epithelium (Meistrich, 1986).

Phyllanthus amarus (Schum and Thonn) is a weed plant in the family Euphorbiaceae, and is a widely distributed small, erect tropical annual herbal whose stem has green capsule and grows upto 10-60 metres tall (Burkill, 1985; Joseph and Raj, 2011). It's phytochemical composition include flavonoids, alkaloids, tannins, saponins, phenols, resins, lignans, terpenes, carotenoids, essential oils, fatty acids and steroids (Sharma *et al.*, 1993).

Spermatogenesis occurs in the seminiferous tubules of the testes, influenced by endocrine, autocrine and paracrine factors (O' Donnell *et al.*, 2011). Morphological variations within the seminiferous tubular content may be due to toxic, physiological or apoptotic germ cell attrition (Kerr, 1992). This is because the spermatogonia is most susceptible to toxicity and the phenomenon is often followed by reconstitution of the seminiferous epithelium from surviving

stem cell spermatogonia which are known to be less sensitive to toxic influence because they less frequently divide (Vidal and Whitney, 2014). Hence, histopathological examination of the testes and epididymis has been described as the most sensitive means to detect effects on spermatogenesis (Vidal and Whitney, 2014). The anti-fertility property of *Phyllanthus amarus* (*P. amarus*) in the testes and epididymis is morphologically evaluated in this study and compared with previous submissions.

MATERIALS AND METHOD

Harvesting and Preparation of Extract:

The stem and leaves of *Phyllanthus amarus* were collected from the premises of University of Benin, Benin city, Nigeria, The plant was identified and authenticated in the Department of Pharmacognosy, University of Benin, Benin-City. The leaves of the plant were washed, cleared of debris, shade-dried and later oven-dried at 50-60°C. The plant was grinded to powdered form and subjected to ethanolic extraction using Soxhlet apparatus to obtain 8.2 kg yield.

Experimental Animals:

Twenty (20) Adult male Wistar rats bred at the Animal House in the Department of Anatomy, University of Benin, were kept in the same location for the experiment, in cages at room temperature (25°C). Approval to carry out the experiment was obtained from the Department, and the procedure was in compliance with the guidelines for use of experimental animals (Canadian Council of Animal Care, 1985). The animals were fed on livestock grower's mash and water *ad libitum* throughout the 12 weeks duration of experiment. The rats were categorized into two groups, A and B of ten (10) rats per group. Group A served as the control and received 1 ml of distilled water only while group B was administered 250 mg/kg ethanolic extract of *P. amarus* in 1 ml of distilled water. The administered dose was in cognizance of the LD₅₀ of the extract and in line with previous studies (Rao *et al.*, 1997; Lawson-Evi *et al.*, 2008). The Body weight of the experimental animals was noted before and at the end of the experiment.

Sperm Analysis

Assessment of epididymal sperm parameters

This was assessed by adopting the conventional method (Raji *et al.*, 2003).

Volume/Dilution: Into 5 ml physiological saline, minced right epididymis using anatomic scissors was placed in a rocker for 10 min and allowed to incubate at room temperature for 2 min. Semen from the rat of 0.5 ml (500 µl) was diluted 1 in 20 (100µl in 1900µl) of physiological saline (0.85 %).

Count: Total sperm number was determined using the Neubauer's counting chamber (haemocytometer). Ten microlitre of diluted sperm suspension was transferred to each counting chamber of the haemocytometer and was allowed to settle for 5 min. The chamber was then placed under a binocular light microscope using an adjustable light source. Sperm cells were counted in five 16-celled squares. The sperm count was calculated, multiplied by 5 and expressed as $X \times 10^6 \text{ ml}^{-1}$ where X is the number of spermatozoa in a 16 cell-square.

Sperm Progressive motility: Sperm motility was evaluated following the modified procedure (Saalu *et al.*, 2009). A small drop (10 μ l) of semen stored at 35°C was placed on a clean slide and cover-slipped. This was examined under x400 magnification lens of a light microscope. Motility was evaluated from three different fields in each sample. The mean of the three estimations was used as the final motility assessment.

Sperm morphology: The sperm cells were evaluated with the aid of light microscope at a magnification of x400. Caudal sperm were taken from the original dilution for motility and diluted 1: 20 with 10 % neutral buffered formalin (Sigma-Aldrich, Oakville ON, Canada). Sperm from the samples were observed for morphological anomalies (Carlsen *et al.*, 1992; Atessahin *et al.*, 2006). A spermatozoon was considered abnormal morphologically if it had one or more of the following features: rudimentary tail, round head and detached head (Saalu *et al.*, 2009).

Histology

After completion of treatment, the animals were sacrificed under anesthesia, and via midline abdominal incision, the testis and epididymis were harvested. The organs were fixed in Bouin's fluid for 24 hours, after which they were processed with automated tissue processor and stained with haematoxylin and eosin (Drury and Wallington, 1980). Photomicrographs were obtained at magnification x40 and x400..

Data Analysis

Data were presented as Mean \pm SEM. Means separation was by Duncan multiple range test (Duncan, 1957) and significant differences between the means were determined by student t-test at ($p < 0.05$).

Table 1: Showing Treatment Regimen of the Experimental Animals

Groups	Treatment Regimen
Group A (Control)	Received normal feed and water <i>ad libitum</i> without administration of extract
Group B (<i>P.amarus</i> -treated for 12 weeks)	Received 250 mg/kg body weight of <i>P.amarus</i> together with feed and water <i>ad libitum</i> .

RESULTS

Physical Finding:

The results of the mean initial and final weight values in the experimental animals (Table 2), revealed that in group A (Control), the mean value of the initial weight was 208 \pm 4.06 g, while the final mean weight value was 218 \pm 1.23 g. In group B, the mean value of the initial weight was 212 \pm 4.06 g, while the final mean weight value was 221 \pm 1.00 g. From the results, there was no significant difference ($p > 0.05$) between the body weight of the treated animals compared to the control.

The mean testicular weight (right and left) of Group A was 1.41 ± 0.03 g while the mean testicular weight of the right and left testes of group B was 1.43 ± 0.01 g. The result of the right and left mean epididymal weight of the control group A was 0.39 ± 0.01 g and that of group B was 0.40 ± 0.01 g. From the results, there were no significant differences ($p > 0.05$) between the mean testicular and epididymal weight of the treated group compared to control.

Sperm Analysis

The result of the sperm analysis of the control group revealed total sperm count was 54.3 ± 1.16 for the control and 32.5 ± 1.04 ($\times 10^6/\text{MI} \pm \text{SEM}$) for the treated group B. Sperm motility was 77.1 ± 2.01 ($\times 10^6/\text{MI} \pm \text{SEM}$) for the control and 41.3 ± 2.14 ($\times 10^6/\text{MI} \pm \text{SEM}$) for the treated group B. The value for morphologically viable sperm in group A (control) was 76.2 ± 1.08 ($\times 10^6/\text{MI} \pm \text{SEM}$) and 49.0 ± 1.33 ($\times 10^6/\text{MI} \pm \text{SEM}$) for the treated group B. The results generally indicated significantly ($p > 0.05$) decreased values in the treated group B of total sperm count, motility and viability compared to the control.

Histopathological Findings:

The rats treated with ethanolic extract of *P.amarus* showed various degrees of testicular degeneration compared to control (group A). The seminiferous tubules of the rats in the control group showed normal blood vessels, germ cells undergoing maturation division, lumen of seminiferous tubule containing some spermatozoa (LU), Testicular interstitium with Leydig cell (Plates 1 & 2) The testes of the rats in the treatment group B showed lumen with scanty spermatozoa, distorted seminiferous epithelium, arrested differentiation and progression of germ cells into the lumen, altered distribution of germ cell series across seminiferous tubule and obvious lumen with marked hypocellularity (Plates 3 & 4).

The epididymis of rats in the treatment group B showed epididymis with thickened epithelial lining and lumen with scanty and moderate clusters of spermatozoa (Plates 5 - 8).

Table 2: Initial and Final Mean Body Weight values between the groups of Experimental Animals

Groups	Mean of Initial Weight and SEM (g)	Mean of Final Weight and SEM (g)
A	208 ± 4.06	218 ± 1.23
B	212 ± 4.06	221 ± 1.00

(*) Significant difference ($p < 0.05$)

Table 3: Mean Testicular Weight of Experimental Animals

Groups	Mean Testicular Weight and SEM (g)
Group A	1.41±0.03
Group B	1.43±0.06

(*) Significant difference (p<0.05)

Table 4: Mean Epididymal Weight of Experimental Animals

Groups	Mean Epididymal Weight (g)
Group A	0.39±0.01
Group B	0.40±0.01

(*) Significant difference (p<0.05)

Table 5: Mean values of Sperm Parameters between the groups of experimental Animals

Groups	Mean of Total Sperm Count X10 ⁶ /MI ± SEM	Mean of Sperm Motility X10 ⁶ /MI ± SEM	Mean of Sperm Viability X10 ⁶ /MI ± SEM
A	54.3±1.16	71.1±2.01	76.2±1.08
B	32.5±1.04*	41.3±2.14*	49.0±1.33*

(*) Significant difference (p<0.05)

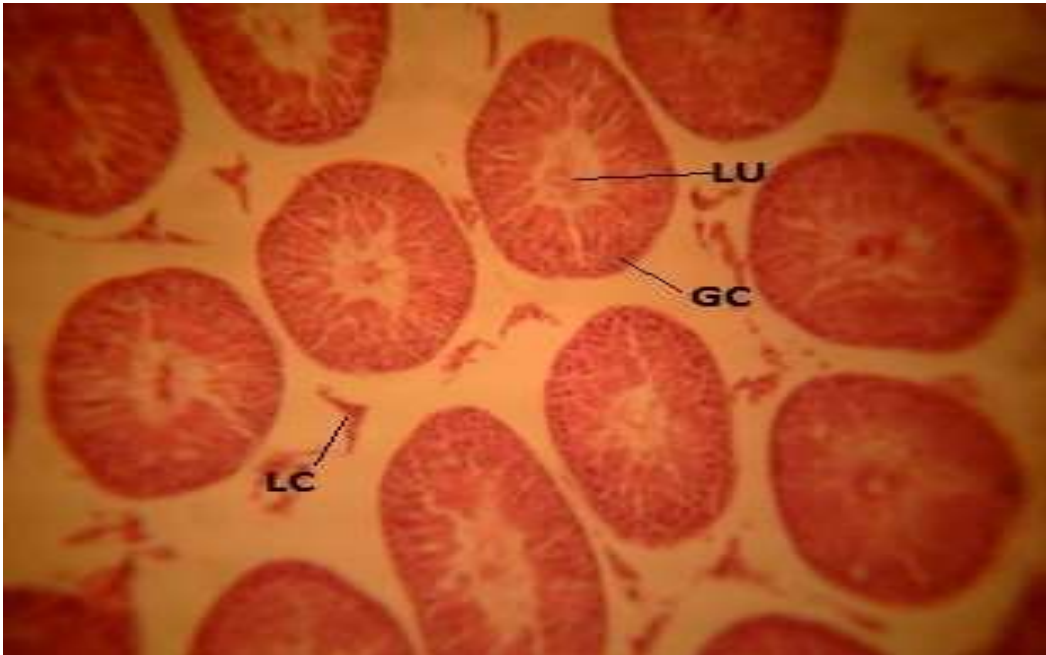


Plate 1: Group A (Control) Slide of the testis showing seminiferous tubules, germ cells undergoing early maturation division (GC), Lumen of seminiferous tubule containing some spermatozoa (LU), Testicular interstitium with Leydig cell (LC). (H&E) x40

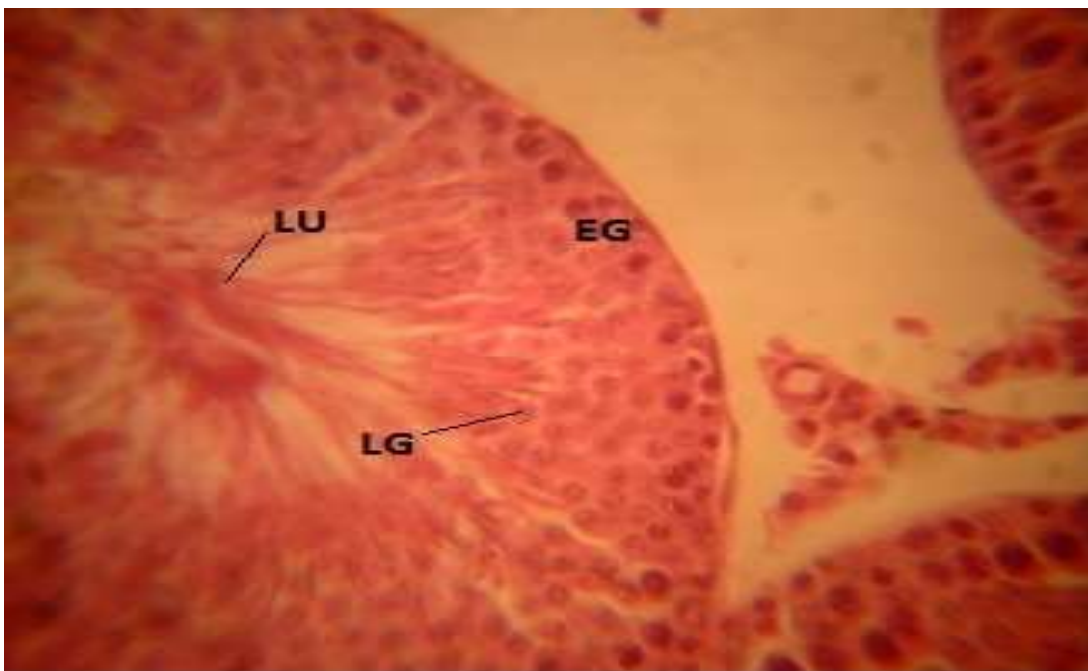

Plate 2: Group A (Control) Slide of the testis showing early germ cells in seminiferous epithelium differentiating (EG), Late germ cells (LG), Lumen of seminiferous tubule (LU) enriched with matured spermatozoa (H&E) x400

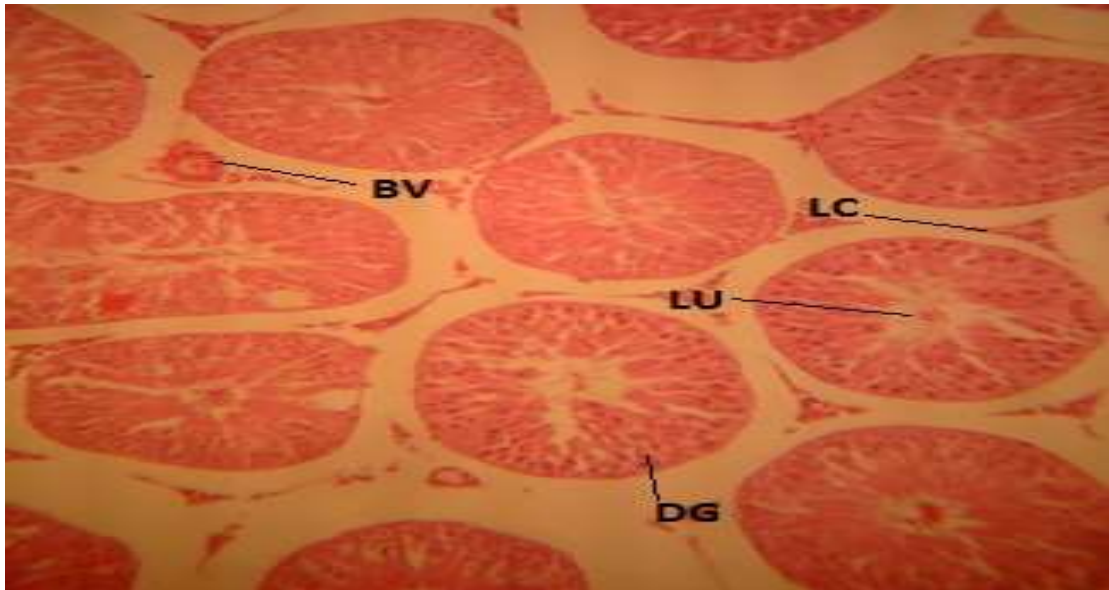


Plate 3: Group B slide of *P. amarus*-treated testis showing differentiating germ cells (DG), lumen of seminiferous tubule with scanty spermatozoa (LU), testicular interstitium with Leydig cell (LC) (H&E) x40.

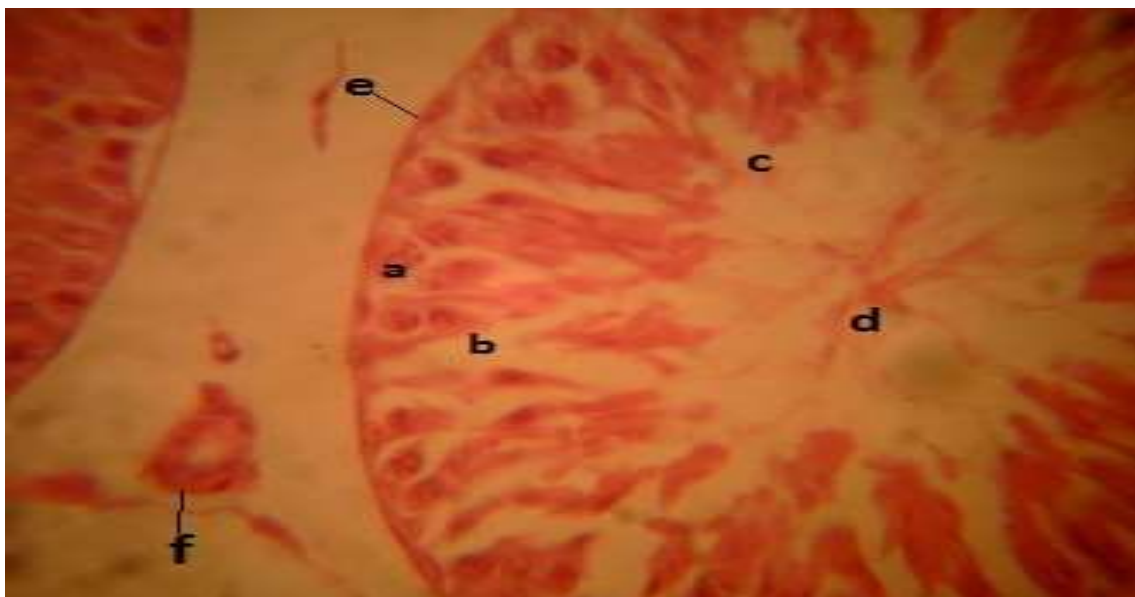

Plate 4: Group B showing seminiferous tubule, germ cell series in altered distribution across the seminiferous epithelium (a), distorted seminiferous epithelium (b), arrested differentiation and spermatogenic arrest (c), lumen with marked hypocellularity (d) Basement membrane (e), testicular interstitium with Leydig cells (f) (H&E) x400

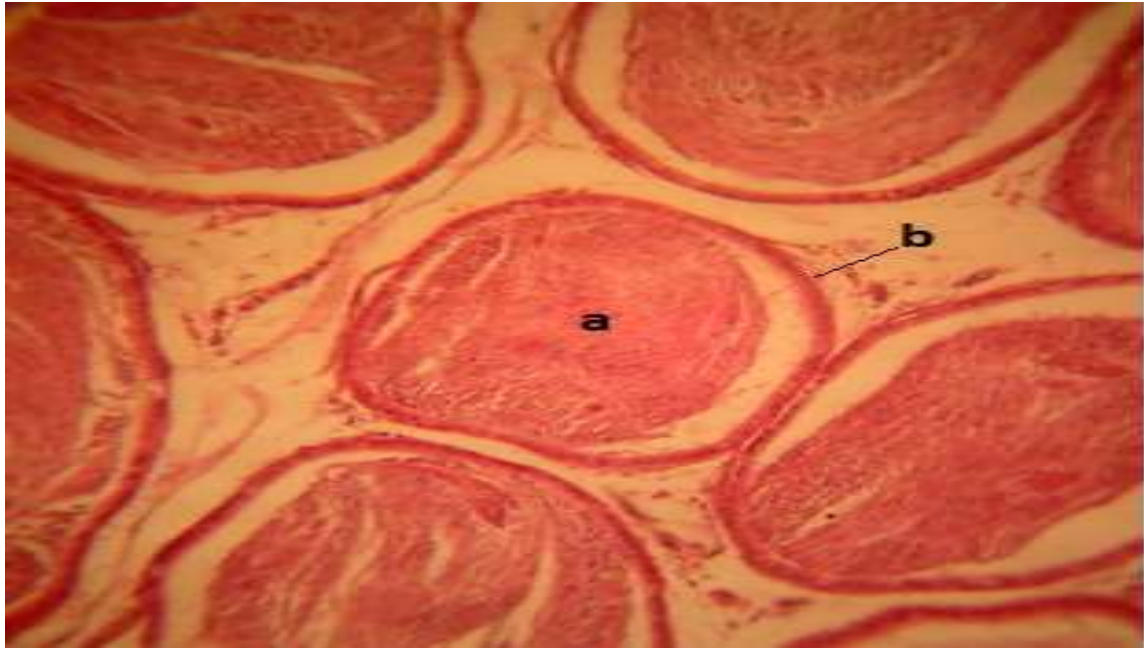


Plate 5: Group A Control slide of the epididymis showing lumen with rich content of Spermatozoa (a), Normal lining of the epididymis (b). (H&E) x40

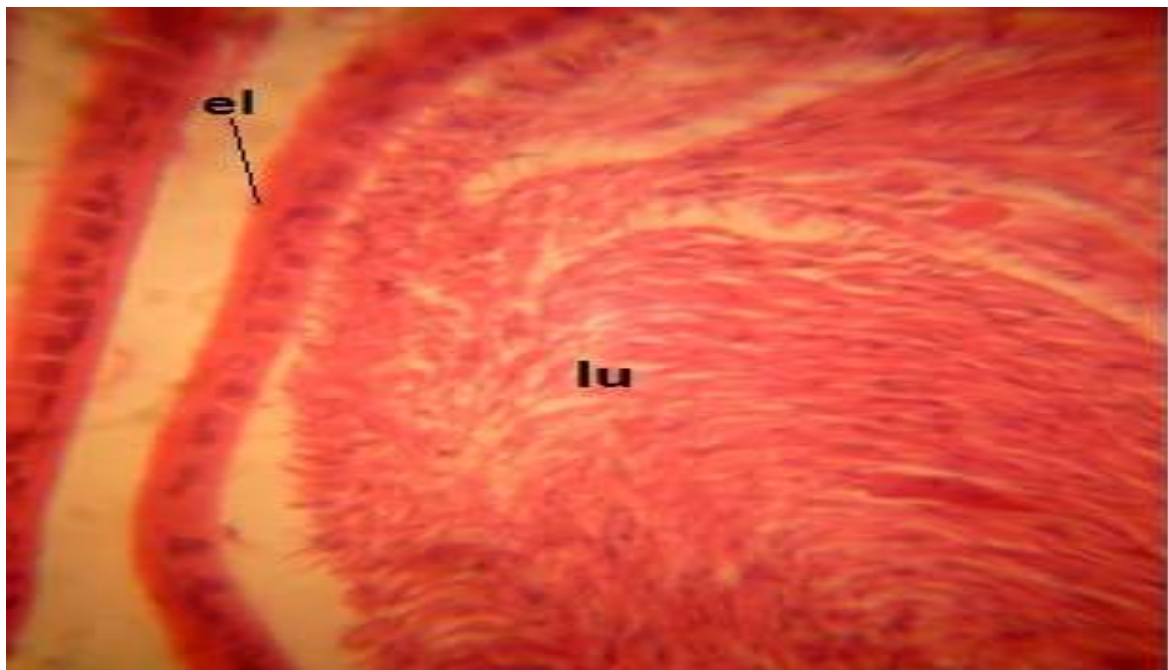


Plate 6: Group A Control Slide of the epididymis showing lumen of the epididymis with spermatozoa (lu), Normal epithelial lining of the of the epididymis (el). (H&E) x40

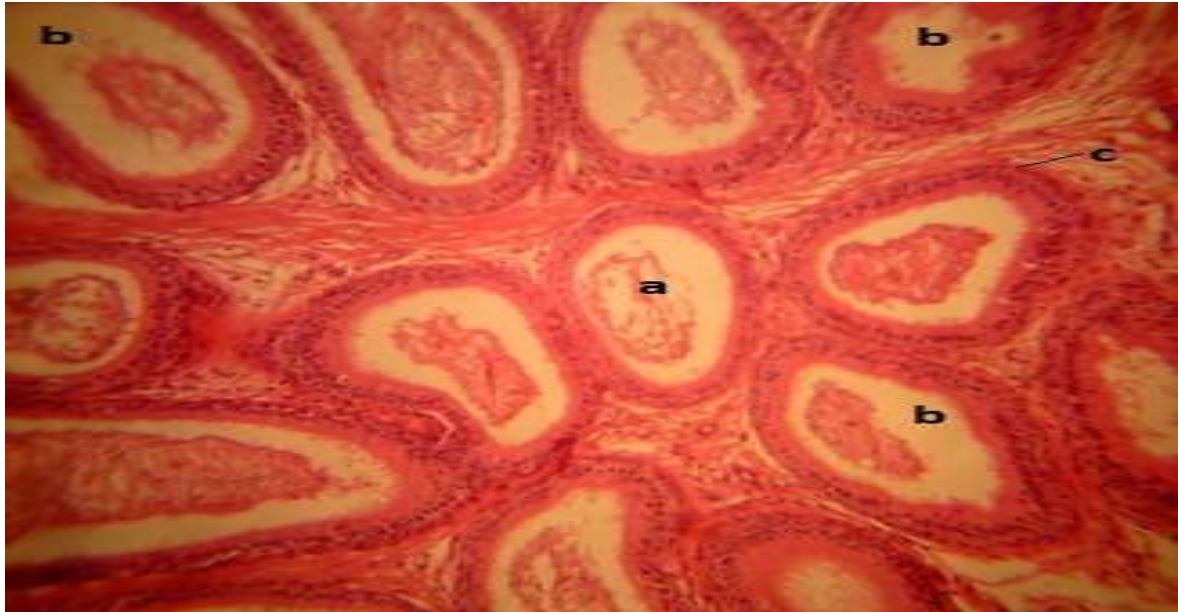


Plate 7: Group B slide of *P. amarus* -treated epididymis showing scanty and moderate clusters of spermatozoa in the lumen (a), areas of depleted spermatozoa in the lumen (b), Epithelial lining of the epididymis with no remarkable change (c). (H&E) x40

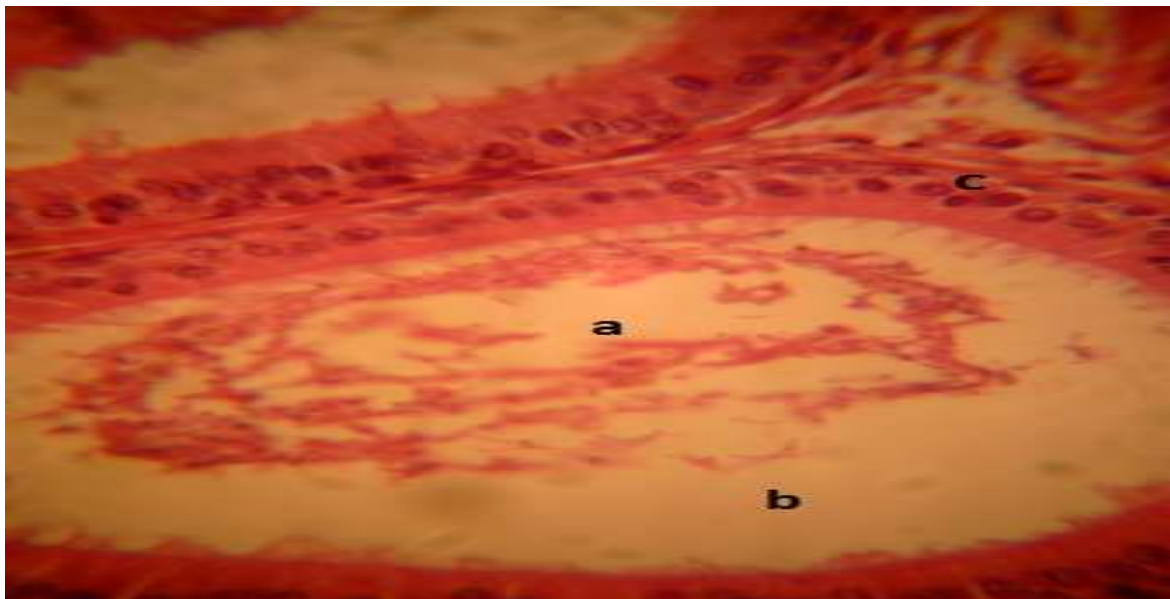


Plate 8: Group B slide of *P. amarus*-treated epididymis, with lumen showing clusters of spermatozoa and necrotic damage(a), areas of hypocellularity due to depletion of spermatozoa (b), and thickened epithelial Lining (c). (H&E) x400

DISCUSSION

Presently, condoms and surgical vasectomy are the popularly canvassed safe and effective methods of contraception in men while research into pills from synthetic and natural products is considered as also viable alternative (O'Rand *et al.*, 2018). Hence phytochemicals with proven reversible effects on male fertility has become interesting to researchers.

This study on the effects of *Phyllanthus amarus* in the Wistar rats led to no significant change in the body and organ weight ($p>0.05$) in the treated rats compared to control. This insignificant change in the body and organ weight by *P. amarus* on treated animals supports previous finding (Ogbomade *et al.*, 2014). However, significant variation ($p<0.05$) existed between the treated animals and the control on examining the sperm count, motility and morphology. This is because *P. amarus* significantly caused reduction in the sperm count, sperm motility and the morphology, a finding which is consistent with earlier report (Ezeonwu, 2011) that found significant reduction in sperm count, motility and viability as well as diminished seminal fluid fructose levels in animals treated with a related specie of the plant. Decreased amount of mature spermatozoa was also reported (Manjrekar *et al.*, 2008) and testicular toxicity with altered anti-oxidant status (Bandekar *et al.*, 2016) in related studies.

Histological assessment of the effects of *P. amarus* in the testes revealed seminiferous tubules with germ cells in altered distribution across the seminiferous epithelium and the adluminal compartment was devoid of the usual cellular aggregates of spermatozoa and marked by areas with hypocellularity, which is indicative of arrested spermatogenesis. Similarly, the epididymal lumen contained scanty and moderate clusters of spermatozoa with areas of depletion. These are indicative of anti-fertility property of *P. amarus* which implies that the plant could have contraceptive potentials in the male (Rao *et al.*, 1997). The finding of these degenerative changes with *P. amarus* is also supported by previous reports (Asare *et al.*, Ogbomade *et al.*, 2014) who related the anti-fertility findings to the influence of hormonal interplay in the testis. High levels of follicle stimulating hormone and low levels of luteinizing hormone and testosterone were attributed to the observed reduction in sperm parameters (Ogbomade *et al.*, 2014). This is understandable from previous studies on the role of these hormones in mediating spermatogenesis (O'Donnell *et al.*, 2011).

Phyllanthus amarus, a commonly observable perennial weed of prominence in the tropics is seen in this study to possess inhibitory effect on the on spermatogenesis, a parameter that could be of importance in male fertility.

REFERENCES

- Asare, G. A., Bugyei, K., Fiawoyi, I., Asiedu-Gyekye, I. J., Gyan, B., Adjei, S., Addo, P., Otu-Nyarko, L., Nyarko, A. (2013). Male rat hormone imbalance, testicular changes and toxicity associated with aqueous leaf extract of an antimalarial plant: *Phyllanthus niruri*. *Pharm Biol*, 51(6): 691-699.
- Atessahin, A., Karahan, I., Turk, G., Gur, S., Yilmaz, S., Cerebasi, A. O. (2006). Protective Role of Licopene on Cisplatin-induced Changes in Sperm Characteristics, Testicular Damage and Oxidative Stress in Rats. *Reprod. Toxicol.*, 21: 42 – 47.
- Bandekar, R., Marar, T., Thayil, L. (2016). Testicular toxicity of aqueous extract of *Phyllanthus niruri* in male Wistar rat. *Int J. Res. Biosciences*, 5(1): 32-38.

- Burkill, H. M (1985). In: The Useful Plants of West Tropical Africa. Kew UK: Royal Botanical Gardens, 2nd edition. Vol. 2. Pp. 169–197.
- Canadian Council of Animal Care, (1985). Guide to the Handling and Use of Experimental Animals. Ottawa, USA: NH Publications, vol. 23, Pp: 45 – 47.
- Carlsen, E., Giwercman, A., Keiding, N., Skakkebaek, N. E (1992). Evidence for decreasing Quality of Semen during past 50 years. *BMJ*, 305: 609 – 613.
- Drury, R. A. B., Wallington, E. A (1980). Light Microscope and Slide Preparation. Carleton's Histological Technique, 5th ed., Oxford University Press, London. Pp.1-4.
- Duncan, D. B (1957). Multiple Range Test for Correlated and Heteroscedastic Means. *Biometrics*, 13: 164 – 176.
- Joseph, B and Raj, S. J. (2011). An overview: Pharmacognostic properties of *Phyllanthus amarus* Linn. *International Journal of Pharmacology* 7(1): 40-45.
- Kerr, J. B. (1992). Spontaneous degeneration of germ cells in normal rat testis: assessment of cell types and frequency during the spermatogenetic cycle. *J Reprod Fertil.*, 95: 825-830.
- Lawson-Evi, P., Eklu-Gadegbeku, K., Agbonon, A., Aklikokou, K., Moukha, S., Creppy, E. E., Gbeassor, M. (2008). Toxicological assessment on extracts of *Phyllanthus amarus* Schum and Thonn. *Scientific Research and Essay*, 3(9): 410-415.
- Manjrekar, A. P., Jisha, V., Bag, P. P., Adhikary, B., Pai, M. M., Hedge, A., Nandini, M. (2008). Effects of *Phyllanthus niruri* Linn treatment on liver, Kidney and testes in CCL4-induced hepatotoxic rats. *Indian Journal of Experimental Biology*, 46(7): 514-520.
- Meistrich, M. L. (1986). Critical components of testicular function and sensitivity to disruption. *Biol Reprod.*, 34: 17-28.
- Mooradian, A. D., Morley, J. E., Korenman, S. G. (1987). Biological actions of androgens. *Endocr. Rev.* 8, 1-28.
- O'Donnell, L., Nicholls, P.K., O'Bryan, M. K., McKLachlan, R. I., Stanaton, P. G (2011). Spermiation. The Process of Sperm Release. *Spermatogenesis*, (1): 14 – 35.
- O'Rand, M. G., Hamil, K. G., Adevai, T., Zelinsky, M. (2018). Inhibition of sperm motility in male macaques with EP055, a potential non-hormonal male contraceptive, *PLOS ONE*, 13(4): e0195953.
- Ogbomade, R. S., Chike, C. P. R., Adienbo, O. M. (2014). Evaluation of anti-fertility effects of aqueous extract of *Phyllanthus amarus* in male Wistar rats. *The Experiment*, 27(3): 1874-1879.
- Raji, Y., Udoh, U. S., Mewoyeka, O. O., Okonye, F. C., Bolarinwa, A. F (2003). Implication of Reproductive Endocrine Malfunction in Male Infertility Efficacy of *Azadirachta indica* Extract in Rats. *Afr Med Med Sci.*, 32: 159 – 165.
- Rao, M. V., Shah, K. D., Rajani, M. (1997). Contraceptive effects of *Phyllanthus amarus* extract in the male mouse (*Mus musculus*), *Phytotherapy Research*, 11: 594-596.
- Saalu, L. C., Osinubi, A. A., Oguntola, J. A., Adeneye, I. O., Benebo, A. S (2009). The Delayed Testicular Morphologic Effects of Doxorubicin and the Rejuvenating Role of Grape Fruit Seed Extract. *Int. J. Pharmacol.*, 6: 192 – 199.
- Sharma, A., Singh, R. T., Handa, S. S. (1993). Estimation of Phyllanthin and hypophyllanthin by high performance liquid chromatography in *Phyllanthus amarus*. *Phyto Chem Anal.*, 4: 226-229.
- Sundaram, K., Witorsh, R. J. (1995). Toxic Effects on the Testes. In: Witorsh RJ (Ed.) *Reproductive Toxicology*. New York: Raven Press, p. 99-121.
- Vidal, J. D., Whitney, K. M. (2014). Morphological manifestations of testicular and epididymal toxicity. *Spermatogenesis*, 4(2): e979099.