

## **A Rare Case of Albright's Hereditary Osteodystrophy presenting as Recurrent Hypocalcemic Tetany**

**Richmond Ronald Gomes<sup>1</sup>**

Associate Professor, Department of Medicine  
Ad-din Women's Medical College Hospital, Dhaka

---

**Citation:** Gomes R.R. (2022) A Rare Case of Albright's Hereditary Osteodystrophy presenting as Recurrent, Hypocalcemic Tetany, *International Journal of Dentistry, Diabetes, Endocrinology and Oral Hygiene*, Vol. 4, No.2, pp, 28-34

---

**ABSTRACT:** *An internist with an eagle's eye can diagnose many hidden disease through careful examination. One such hereditary metabolic disorder is Albright's Hereditary Osteodystrophy (AHO). Characteristic presentations in an individual affected by AHO were short stature, obesity, mild mental retardation and brachydactyly especially of 4<sup>th</sup> and 5<sup>th</sup> digits, which are the phenotypic features of genetic mutation. Pseudohypoparathyroidism (PHP) is characterized by inability of the body to respond appropriately to parathormone, mainly characterized by hypocalcaemia, increased serum parathormone concentration, insensitivity to the biological activity of parathormone and hyperphosphatemia. AHO when seen in association with resistance to parathormone (PTH), it is called PHP. Here is a case report of 22-year-old female patient with AHO with distinctive physical characteristics who presented to us with recurrent hypocalcaemic tetany.*

**KEY WORDS:** hyperphosphatemia, hypocalcaemia, pseudohypoparathyroidism, brachydactyly, Albright hereditary osteodystrophy (AHO).

---

## **INTRODUCTION**

Albright's hereditary osteodystrophy(AHO) is a form of osteodystrophy,<sup>1</sup> and is classified as the phenotype of pseudohypoparathyroidism type 1A; this is a condition in which the body does not respond to parathyroid hormone.<sup>2</sup> It is characterized by a metabolic disorder that can be inherited in an autosomal dominant, autosomal recessive, or X-linked dominant form. The disorder bears the name of Fuller Albright, who characterized it in 1942.<sup>3</sup> He was also responsible for naming it "Sebright bantam syndrome," after the Sebright bantam chicken, which demonstrates an analogous hormone insensitivity. Much less commonly, the term pseudohypoparathyroidism (PHP) and acrodyostosis.<sup>3</sup> Martin-Albright syndrome is used, this refers to Eric Martin.<sup>4</sup> It is a heterogeneous group of disorder characterized by hypocalcemia, hyperphosphatemia, increased serum concentration of parathyroid hormone, and insensitivity to the biological activity of PTH due to resistance toward parathyroid hormone. This defect is caused by gene mutation in *GNAS1* gene, which results in partial or total deficiency of Gs-alpha activity and thus involves the

impairing of function of the biochemical pathways responsible for the activation of parathormone receptors; therefore, it leads to resistance to PTH action.

Apart from features that are common to all forms of hypoparathyroidism, i.e., short stature that is usually evident in late childhood), obesity, mental retardation, subcutaneous ossification, brachydactyly

(metacarpal and metatarsal shortening), hypogonadism, and hypothyroidism.<sup>5</sup>Dental defects include enamel hypoplasia and blunt root development. It is an important cause of delayed eruption of teeth.<sup>6</sup>

There is considerable phenotypic variability of the disease in the same family and in the same generation.

**Case report:** A 22-year-old married housewife with a history of repeated hypocalcaemic tetany, diagnosed at 2 years, presented with two new episodes of generalized tonic-clonic seizures and tingling sensation over perioral regions and both upper and lower limbs for last 2 days. She did not have a history of vomiting, loose stool, head trauma, fever, headache, stroke, hypertension, diabetes. But her mother, who died of stroke 3 years back, had history of repeated seizure, the cause of which was not evaluated. There was no history of consanguinity of marriage among her parents. Her birth history was uneventful with no history of any perinatal asphyxia, pre term labour or low birth weight. The patient denied any thyroid or other neck surgery but her milestone of development was delayed and she had history of delayed eruption of her tooth. Her menstrual history was irregular and she had no issues in her 6 years of marital life. She also had history of recurrent tingling of her limbs and seizure for last 8 years which was managed conservatively in local hospitals with irregular intake of anti epileptics. Physical examinations revealed that she is short statured, overweight with short neck (figure 1) (height: 152cm, weight: 62kg, body mass index [BMI]: 26.8).Round-shaped face(figure 2), and brachydactyly were present as evidenced by knuckle knuckle dimple dimple sign (archibald's sign) (figure 3).




Figure 1, 2 and 3 showing short stature, round face and positive Archibald sign respectively.

Her vital signs were as follows: blood pressure was 110/70 mm Hg; pulse rate was 74 beat per minutes; respiratory rate was 20 breaths per minutes; and body temperature was 36.3°C. Oral examination revealed multiple carious teeth with halitosis. There were hypoplastic teeth with no enamel hypoplasia. Neurological examination revealed clear consciousness, with no cranial nerve abnormalities, no tremor or no bradykinesia. In addition to some cognitive impairment, on examination she had a positive Trousseau sign (flexion of the wrist and metacarpophalangeal joints when blood pressure cuff is inflated above the systolic blood pressure) and Chvostek sign (twitching of the ipsilateral facial muscles on tapping on the face at a point just anterior to the ear and just below the zygomatic bone). Laboratory studies: CBC was normal in all cell line, s. electrolyte- sodium 139 mmol/l, potassium 4.4 mmol/l,  $\text{HCO}_3^-$  28 mmol/l, s. creatinine 0.47 mg/dl (normal 0.2- 1.1 mg/dl), s. calcium 5.2 mg/dL (8.5–10.5 mg/dL), s. albumin 47.63 (so corrected calcium 3.79 mg/dl), s. phosphate 6.69 mg/dL (2.6–4.5 mg/dL), s. magnesium 0.7 mmol/l (normal 0.66- 1.2 mmol/l) intact parathyroid hormone 218.6 pg/dL (11–67 pg/dL) with TSH 11.7 (normal 0.35- 5.5), LH....., FSH..... and 25-hydroxyl vitamin D 31.33 ng/dL (30–65 ng/dL). MT was non conclusive, ANA was negative (5.5 U/ml). Urinary calcium revealed hypocalciuria < 2. CT of the brain revealed bilateral symmetrical calcification of both choroid plexus of posterior horn of lateral ventricles (figure 4). EEG revealed features suggestive of secondarily generalized epilepsy. X ray of hand revealed short 4<sup>th</sup> and 5<sup>th</sup> metacarpals (figure 5). A line is drawn transgential to the distal portion of the fourth and fifth metacarpals. In normal subjects, it should not intersect the third metacarpal. This sign is positive in our patients (Archibalds sign). Genetic evaluation could not be done due to unavailability in our country. OPG revealed hypoplastic anterior teeth (figure 6).

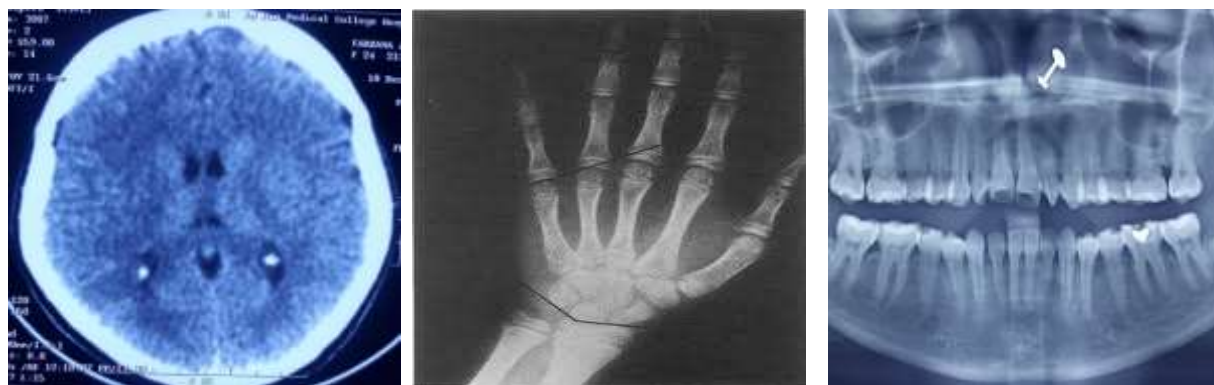

Figure 4, 5 and 6 showing CT brain with bilateral calcification of choroid plexus of posterior horn both lateral ventricles, x-ray hand with short 4<sup>th</sup> and 5<sup>th</sup> metacarpals and OPG with hypoplastic anterior teeth respectively.

Treatment plan included medication with 1 gram of levetiracetam, 2gms of Calcium acetate orally, 100mcg vitamin D3 daily, thyroxine 50 mcg daily was started as initial phase of treatment. Patient was recalled after three weeks wherein hematological investigations were carried out. There was a considerable increase in serum calcium level to 8.8mg%, serum phosphate recorded was 4.7mg%

which was reduced compared to initial values and PTH levels were 92.5pg/dl which showed considerable reduction from the aforementioned values.

## DISCUSSION

Parathormone is the principal hormone that maintains serum calcium and phosphorous levels in the body. Parathormone functions mainly includes, enhanced distal tubular resorption of calcium, promotion of bone resorption, increased synthesis of 1,25 hydroxy vitamin D, therefore, leading to enhanced intestinal calcium absorption<sup>7,8,9,10</sup>.

PHP is a term applied to a heterogeneous group of disorders where the most common feature is the resistance to parathyroid hormone.<sup>11</sup> Most of the patients have hypocalcemia and hyperphosphatemia despite elevated concentration of parathyroid hormone in plasma. This is due to the loss of the phosphaturic action of parathyroid hormone and reduced formation of 1, 25-dihydroxy vitamin-D with resultant defective mobilization of calcium from bone and reduced GIT absorption of calcium. PHP type Ia is associated with resistance to multiple hormones in addition to parathyroid hormone and with a constellation of physical abnormalities collectively termed as AHO.<sup>12</sup>

Genetic studies done to know the etiology of AHO has revealed mutation of GNAS1 gene located on 20q13-11 as the culprit gene<sup>8</sup>.

In literature, AHO has been reported with characteristic features like short stature, round face, flat, wide and low nasal bridge, short neck, flat occiput, brachydactyly of 4<sup>th</sup> and 5<sup>th</sup> digits (usually bilateral,<sup>13</sup> due to premature skeletal development and closure of epiphysis), knuckle dimples in the clenched fists, short broad nails, osteoporosis, cataract, dementia, epileptic seizures, ankylosis of TMJ, rheumatoid arthritis of hand and foot joints, cone shaped epiphysis, thickened calvaria, basal ganglia and choroid plexus calcification and subcutaneous ossification<sup>9,10,14,15</sup>. Our case also coincides with these findings. Obesity and mild mental retardation are often seen in these patients because lipolytic factors act by stimulating cAMP formation, and abnormalities in cAMP metabolism are associated with learning defect. In our case, we noticed a typical silver beaten appearance of skull.

The present case gave a familial history of AHO which is not in agreement to studies done by Monica Gomes et al., but similar to series of erratic cases reported in literature<sup>6,9</sup>. Cases documented previously show preponderance of AHO in female individuals, stating that AHO occurs twice frequently in females than males. In accord with female preponderance are studies done by Davies and Hughes, Fitch N et al., Sunder and Singh, and Erel et al.<sup>14,16,17,18</sup>.

TMJ ankylosis has been reported in case reports by Ambika L & Vaishali K and Goldberg et al., but the presenting case shows no ankylosis of TMJ<sup>9,19</sup>. Basal ganglia and choroid plexus calcification seen in Computed Tomography (CT) has also been reported by Ambika L & Vaishali K, Wilson L & Richard and Seema Kapoor et al., and Livia et al.,<sup>8,9,10,21</sup>. The reason for the focal

accumulation of calcium in basal ganglia can be due to local factors and disturbance of calcium metabolism. Dementia, seizures and Parkinsonism are seen associated with basal ganglia calcification<sup>14,20</sup>.

Oral manifestations in AHO patients include aplasia, thin enamel with enlarged pulp chamber, hypoplasia, hypodontia, pulp calcification, multiple carious teeth, multiple unerupted teeth, crowded anterior teeth, anterior open bite, gingival hyperplasia, gingivitis with spontaneous bleeding and pain<sup>9,10</sup>. In addition, there was also the presence of malocclusion impairing proper oral hygiene and favoring the accumulation of bacterial plaque and calculus.

Patients with PHP have AHO phenotype resistance to G-protein-coupled hormone, attenuated response to urinary phosphate and cAMP excretion after intravenous infusion of synthetic PTH, and decreased Gs-alpha activity<sup>22</sup>. In some patients, this phenotype is found without biochemical evidence of PTH resistance. This has been termed as PPHP.<sup>23</sup> The abnormalities in various types of PHP have been depicted in the Table 1.

Type I	Type II	Pseudopseudohypoparathyroidism
<b>Type Ia (AHO)</b> 1. Multiple hormone resistance 2. Defect proximal to cAMP  <b>Type Ib</b> 1. Physical appearance is normal 2. Resistance limited to renal response to PTH  <b>Type Ic</b> Features of AHO with normal Gs-alpha activity	1. Rarely familial 2. Resistance limited to PTH 3. Defects distal to cAMP formation	Features of AHO without overt hormone resistance

**Table 1: Pseudohypoparathyroidism(PHP)**

A variety of disorders shares certain features in common with PHP type Ia, but in general is readily distinguished from it. Therefore differential diagnosis has to be made before deciding for appropriate diagnosis. Soft tissue ossification is present in myositis ossificans but differ in location (muscle) from that in PHP Ia (subcutaneous). The pattern of metacarpal shortening differs in PHP Ia and Turner syndrome, but the latter is not associated with resistance to PTH. The main difference now remains secondary hyperparathyroidism. Alkaline phosphatase levels are usually increased manifolds in this condition with characteristic appearance of osteitis fibrosa cystica.



All patients with severe symptomatic hypocalcemia should be treated with intravenous calcium. Administration of oral calcium and alpha hydroxylated vitamin-D metabolite such as cholecalciferol remains the mainstay of treatment and with close observation periodically. The dental treatment involves the management of carious teeth along with planning for correction of malocclusion.

## CONCLUSION

The findings of general and oral manifestation of AHO described in our report contribute to the clinical picture of AHO that is developing in the literature. AHO is a longstanding disorder, which needs careful examination and symptomatic treatment. As dentist, careful examination of physical characteristics and thorough evaluation of tooth eruption in accordance with chronological age of the patient can help in early diagnosis of patients with AHO. Multidisciplinary approach can help in accurate diagnosis and on providing prompt treatment to the patient.

## References

1. Rapini, Ronald P.; Bologna, Jean L.; Jorizzo, Joseph L. (2007). *Dermatology: 2-Volume Set*. St. Louis: Mosby. p. 657.
2. "Albright's hereditary osteodystrophy". Genetic and Rare Diseases Information Center (GARD) – an NCATS Program. Retrieved 9 February 2017.
3. F. Albright, C. H. Burnett, P. H. Smith, et al. Pseudo-hypoparathyroidism-example of 'Seabright-Bantam syndrome'; report of three cases. *Endocrinology*, Baltimore, 1942, 30: 922-932.
4. D. Martin, J. Bourdillon. Uncas de tétanieidiopathiquechronique. Échechthérapeutique de la graffe d'un adénomeparathyroïdien. *Revue médicale de la Suisse romande*, Lausanne, 1940, 60: 1166-1177.
5. Weinstein LS. Albright hereditary osteodystrophy. Pseudohypoparathyroidism andGs alpha deficiency. In: Spiegel AM, editor. G-protein, receptors and disease. Totowa; Humana Press; 1998. p. 23-56.
6. Gomes MF, Camargo AM, Sampo TA, Graziozi MA, ArmondMC. Oral manifestation of albright hereditary osteodystrophy. *Rev HospClin* 2002;57:161-6.
7. Prentice R. Pseudohypoparathyroidism: a case report. *The Journal of Clinical Endocrinology & Metabolism*. 1954;14(9):1069–73.
8. Garavelli L, Pedori S, Zanacca C, Caselli G, Loiodice A, Mantovani G, et al. Albright's hereditary osteodystrophy (pseudohypoparathyroidism type Ia): clinical case with a novel mutation of GNAS. *Acta Biomed*. 2005;76(1):45–48.
9. Keluskar LA, Albright V. Hereditary Osteodystrophy: A constellation of Clinical Features. *Journal of Indian Academy Of Oral medicine & Radiology*. 2010;22(4):215–17.
10. Kapoor S, Gogia S, Paul R, Banerjee S. Albright's hereditary osteodystrophy. *The Indian Journal of Pediatrics*. 2006;73(2):153–56.
11. Coe FL, Favus MJ. Disorders of bone and mineral metabolism. 2nd ed. 1998. p. 580-5.
12. Spiegel AM, Weinstein LS. Pseudohypoparathyroidism. In: Scriver, Beaudet, Valle, Sly, editors. The metabolic and molecular bases of inherited diseases. 8th ed. vol. 3. 1965. p. 4205-17.

- 
13. Potts JT Jr. Diseases of parathyroid gland. In: Braunwald, Fauci, Kasper, Hauser, Longo, Jameson, editors. Principles of internal medicine. 15th ed. vol. 2. 2003. p. 2227-47.
  14. Ecsel E, Dündar M, Bayram F, Catakouglu, Candemir Z, Kilicc C. Albright's Hereditary Osteodystrophy and Dementia: A Case Report. *Bull Clin Psychopharmacol*. 2001;11:183–86.
  15. Kotter M, Linglart A, Carel J. Albright hereditary osteodystrophy. *Orphanet Encyclopedia*. 2004 .
  16. Sunder R, Singh M. Pseudohypoparathyroidism: a series of three cases and an unusual presentation of ocular tetany. *Anaesthesia*. 2006;61(4):394–98.
  17. Davies S, Hughes H. Imprinting in Albright's hereditary osteodystrophy. *Journal of medical genetics*. 1993;30(2):101–03.
  18. Fitch N, Opitz J, Herrmann J. Albright's hereditary osteodystrophy: a review. *American journal of medical genetics*. 1982;11(1):11–29.
  19. Goldberg MH, Slaughter TW, Harrigan WF. Pseudohypoparathyroidism with temporo-mandibular ankylosis: report of case. *J Oral Surg*. 1967;25(2):175–81. PubMed PMID: 5226355.
  20. Evans B, Donley D. Pseudohypoparathyroidism, parkinsonism syndrome, with no basal ganglia calcification. *Journal of Neurology, Neurosurgery & Psychiatry*. 1988;51(5):709–13.
  21. Wilson L, Trembath R. Albright's hereditary osteodystrophy. *Journal of medical genetics*. 1994;31(10):779–84.
  22. Chase LR, GL Aurbach GD. Pseudohyperparathyroidism: Defective excretion of 3' 5" - AMP in response to parathyroid hormone. *J Clin Invest* 1969;48:1832-44.
  23. Spiegel AM, Weinstein LS. Pseudohypoparathyroidism. In: Scriver, Beaudet, Valle, Sly, editors. The metabolic and molecular bases of inherited diseases. 8th ed. vol. 3. 1965. p. 4205-17.

Conflict of interest: None declared