

DENTAL IDENTIFICATIONS OF ADOLF HITLER AND EVA BRAUN

Xavier Riaud

DDS, PhD in Epistemology, History of Sciences and Techniques, Laureate and member of the National Academy of Dental Surgery, Free member of the National Academy of Surgery, France

ABSTRACT: *In 2018, Philippe Charlier, a French well-known physician, said he was the man who clearly identified the remains of Adolf Hitler's dead body. It's not the truth. Adolf Hitler was identified by Pr Reidar Sognaes and Dr Ferdinand Strøm in 1973 thanks to his teeth. Their results was published in a great international journal. Here is the true story of this famous dental identification.*

KEYWORDS: dental identifications, Adolf Hitler, Eva Braun

INTRODUCTION

Really Bad Teeth

Hitler [1] had very bad teeth and a very bad breath. Before the war, he asked Blaschke, his dentist, to immobilize his teeth with a dental bridge. He wanted that bridge to be placed for several years. Thus, Blaschke made an unusual and easy-to-recognize solid metal bridge.

End of war...Beginning of the investigation...

On April 30, 1945, Hitler committed suicide. His body was burnt in a bomb crater in the garden of the Chancellery next to a hospital and amongst other corpses which were buried afterwards.

Despite the investigation of British officer Trevor-Roper and despite being approached diplomatically, the Russians did not answer any questions concerning this affair until 1954. It was only that year, when Blaschke's dental prosthetist, Fritz Echtmann, was released from prison, [2]; –he had been interned in Russia for nine years- that the entire world learnt about the exact fate of the Führer and his wife. On October 15, Echtmann stipulated that he had been arrested by the Russian secret services on May 9, 1945 in his house in Berlin. On the same year, once she was also released and back from Russia, Blaschke's assistant, Käthe Heusermann [3] attested to also have been arrested on May 9, 1945.

Post-mortem examinations

The Führer's body was only found again on May 3, 1945 by Smersh agents, the counter-intelligence department in the Soviet Army. On May 8, he was brought in a hospital of Berlin's suburbs to be examined. On May 9, his dentures (Fig. 1) found on the cadaver were shown to the assistant of Hitler's personal dentist [2] and to the dental mechanic who had made them. Echtmann [4] recalled that the Soviets had shown him a lower jaw which had been cremated with two gold bridges and another one divided into nine pieces which was also in gold and which was coming from his jawbone. Indisputably, he remembered the work he

did for Hitler. He was shown a gold-filled bridge, which was similar to that of the mandible that Eva Braun used to wear. When he was imprisoned, he submitted an additional nine-page report on the matter.

In the same time, the assistant identified the various elements of dental prosthesis that were being shown to her. Both of them remembered well the red box in which Hitler's remains were stored, and of the tall blond interpreter who permitted discussions with the Russians.

Those two statements were published and yet, doubts remained. The need of an official report without flaws and coming to an indisputable and irrefutable conclusion became obvious.

First public revelations

In 1965, Yelena Rzevskaya, the blond interpreter whom Echtmann and Heusermann mentioned, published a report entitled «Berlin, May 1945» in a Soviet magazine. This work was published as a book and translated into numerous languages in 1967. This work told how the Russians discovered thirteen charred corpses in the gardens of the Chancellery, how, in the following days, they were examined by a commission of five specialists conducted by lieutenant-colonel Faust Schkarawski in the hospital of Russian field n° 496 of Berlin-Buch.

On the afternoon of May 8, the commission handed over a red box to the Smersh. It contained jawbones and gold bridges from bodies n°12 and 13 who were suspected to be Hitler's and Eva Braun's. This box was handed over to the interpreter.

The following day, the Smersh were looking for Hugo Blaschke, his dental prosthetist and his assistant. At the clinic of Kurfürstendamm, they found out that the dentist had left Berlin for Berchtesgaden under the Führer's command on April 19. However, they succeeded in taking in the two others for questioning.

They were asked about the content of the red box which was shown to them. All that they said was immediately recorded before they had the chance to examine the human remains.

On May 10, the Smersh sent a report to Moscow. It concluded that the two remaining bodies had been identified as Hitler and Eva Braun's remains [4].

The red box and its content were sent back to the Soviet capital.

Lew Besymenski, a Russian journalist

In 1966, Lew Besymenski, a Russian journalist and cultural attaché for West Germany, published a book entitled « Der Tod des Adolf Hitler (Adolf Hitler's death) » which was also translated into several languages including French in 1969 by the Plon Editions. In that work, Colonel Gorbushin's words were quoted, the director of the Russian secret services, those of colonel Schkarawski as well as those of other members of the commission in charge of the post-mortem examination of the corpses. The complete transcriptions of the examination sessions of the thirteen bodies as well as pictures of pieces of bridges could also be found in the book. For the very first time, dental experts from different countries could examine from few post-mortem elements that Hitler and Eva Braun's identification had been carried out. The issue was that Besymenski's book did not give other comparative perspectives of other post-mortem elements. Indeed, the book never mentioned elements from the dictator's dental file as well as his X-rays copies. Consequently, no verification of the final results was made possible [4].

Pr Reidar Sognnaes and his Investigations

In 1971, Dr Ferdinand Strøm from Oslo asked for Dr Reidar Sognnaes's help (Fig. 4), UCLA dental school's former dean (University of California, Los Angeles). Strøm recalled Sognnaes that the Americans had captured Blaschke in Berchtesgaden in November 1945. Thus, there was an interrogation report in the army's archives in Washington. Given Pr Sognnaes's rank, they wondered if he might get further information on that affair.

The preeminent practitioner immediately went to the capital and was allowed to research in the national archives. Soon, he found the American secret services' file on Blaschke's interrogation which was conducted on November/December 1945. Without these files and the X-rays copies, the Nazi recalled Hitler's, Eva Braun's and Bormann's teeth. Comparing with Besymenski's photographs, common features were found and yet differences were also obvious.

After further investigations, Sognnaes found five X-ray copies of Hitler's had, three dating from September 1944 and two from October 21, 1944. This set of photographs was made because the dictator was suffering from sinus problems. Those images gave more details concerning the dental work carried out in his mouth and were indisputable. The professor had found objective documents identifying indisputably Adolf Hitler [5].

Epilogue

During the 6th meeting of the International Academy of Legal Medicine in Edinburgh, Sognnaes and Strøm [6] confirmed the identification of Hitler from his teeth to a group of international experts. The two men published their results in the following article:

Sognnaes R. F. & Strøm F., The odontological identification of Adolf Hitler. Definitive documentation by X-Rays, interrogation and autopsy findings, in Acta Odontologica Scandinavica, Feb. 1973; 31 (1): 43-69 [4,5].

Adolf Hitler's teeth are displayed in a Ukrainian museum. Little information is given via this picture except for a clearly visible periodontal disease with a loss of bony support on the left dental block, which could explain his "bad breath". On the right dental block, there is apparently a dental crown on a second lower premolar n°45.

Eva Braun (1912-1945)

Idyll with the Führer

She met Adolf Hitler [7] in 1929 when she worked for the official photographer of the Nazi Party. After her two suicide attempts, Hitler decided to get close to her by inviting her in his villa next to Munich. By 1936, she was a part of his household at the Berghof. She did not attend public events with him. In 1943, her sister married a SS General who was close to Heinrich Himmler. The dictator used this as an excuse to facilitate his companion's involvement in official duties. In April 1945, she went to Berlin to be by his side in the Führerbunker. She married him on April 29, 1945. They committed suicide together on the 30th.

Doubts remain...

In Besymenski's book which was previously mentioned, there is a picture of a bridge coming from the mouth of body n°13 which was later identified as being Eva Braun's.

Blaschke's assistant and his dental mechanic had identified this prosthesis work. Moreover, the German dentist described it in his notes handed over to the American authorities at the end of 1945. There is no formal reason to doubt those testimonies even though they were all collected in living memory and after the main characters' death.

However, there are no ante-mortem documents concerning Eva Braun's mouth before her death. Many experts considered Besymenski's picture as sufficient proof to identify body n°13.

And yet, many others thought differently.

In June 1981, at a meeting in Bergen, Norway, of the International Association of Forensic Sciences, a preeminent specialist expressed doubts concerning Eva Braun's identification [4].

Strøm et Keiser-Nielsen wondered about the identification

Drs Ferdinand Strøm and Søren Keiser-Nielsen [8] immediately decided to reconsider her identification. They remembered that the photograph in the English edition had shown not only the bridge used all the way as key evidence in this case, but also what was described in the Russian autopsy : «a piece of yellow metal (gold) of irregular shape measuring 6 mm x 3 mm (presumably a filling). »

Apparently, nobody had paid much attention to the filling. Thus, the two men decided to study it carefully and to consider it as full-fledged incriminating evidence.

After a close study of the picture, they were convinced to have a small cast filling, probably a gold filling. The two men could not conceive that Eva Braun would have accepted anything but the best.

With the bridge beside it to allow for a comparison of size, they agreed that this was a filling from an upper bicuspid, lying on a small flat basin with its occlusal surface turned towards the camera.

One question immediately came to their mind [5].

The dental prosthetist's report

With no antemortem documents available concerning Eva Braun's dental status, which one of the postmortem descriptions of her teeth should they rather rely on – Echtmann's, Heusermann's, or Blaschke's? They preferred Echtmann's report. Besymenski kindly sent them a copy of the handwritten German original sketches. When he was imprisoned, the dental mechanic gave a clear description with outlines to the Soviet authorities (Fig. 2 & 3). He described the bridge inserted in the autumn 1944. He also described another bridge made for Eva Braun's left upper jaw. The two men were immediately fascinated by this report.

His sketch of her left side sketch shows the first molar tooth missing, while the second molar has been ground into a cone. A gold crown had been cast and it carried a replacement for the missing tooth in front. It was an extension bridge with an anchor at the other end of the bridge. In Echtmann's sketch, this extension bridge with its anchor is shown to the extreme

left [4]. This bridge was not ready for insertion until April 19th of 1945 and Blaschke who had to leave Berlin hastily never had the chance to insert it. The Russians found the prosthesis on May 9th of 1945, when they searched the emergency dental clinic situated in the cellar of the Reich Chancellery for Blaschke's dental records [9].

On the second drawing, it was equally interesting to find that the upper left second bicuspid carried an inlay, on the chewing surface and the side turning towards the empty space behind (marked with arrow I). Echtmann wrote to the right of the I: «Arrow I. shows the gold filling for the bridge which was cemented in Miss Braun at the beginning of April 1945. By Prof. Blaschke, which I have made. »

Echtmann's sketches indicated no inlays in the other three upper bicuspid. The upper bicuspid concerned was the one that could possibly be the « piece of yellow metal ». The cut-out for the anchor was the explanation of its irregular shape [8].

Comparative study

« The two experts decided to assess the size of the lower jaw bridge and the gold inlay seen in the Russian photograph. They selected two natural teeth: a lower right first molar and a lower right second bicuspid. Their roots were cut off and their lingual surfaces ground away. The remaining crown parts were waxed together in a double pontic. They created an imitation in natural size of the replacement of the same two teeth in the bridge from Body No.13. Then they selected an upper left second bicuspid. They drilled in it a standard cavity for a gold inlay. The cavity filled with dark-blue wax and a cut-out for an anchor made. The wax inlay was taken out, placed beside the double pontic with its chewing surface towards the viewer. A photograph was taken in which the natural teeth of the double pontic came out the same size as the corresponding artificial teeth in the photograph of the bridge from Body No.13. The wax inlay could be compared with a reasonable degree of accuracy to the gold inlay in the Russian photograph. The wax inlay bears a more than striking resemblance to the gold inlay taken from the Body No.13. It convincingly corroborates the Russian identification of Body No.13 as Eva Braun [8]. »

CONCLUSIONS

On April 30, 1945, Hitler and Eva Braun committed suicide. Despite the Soviet authorities who tried to hide their death and allowed uncertainty to persist on their death, the veil was finally lifted on this mystery by two dentists in 1973 as far as the dictator is concerned and in 1981 for his companion.

Therefore, the work accomplished by Pr Sognaes and le Dr Strøm was unanimously recognized by international critics [16].

Who was Reidar Sognaes (Fig. 4) ?

Reidar was born on November 6, 1911 in Bergen, Norway. He started the dental art at the University of Oslo before leaving for the United States in 1938 as an intern at the Forsyth Dental Infirmary for Children Boston.

He continued his apprenticeship in the Rochester School of Medicine and the New York University College of Dentistry where he got a Master's degree in Physiology and a PhD in pathology in 1941.

During World War II, he served as Captain in the Royal Norwegian Air Force.

After the conflict, he taught at Harvard University. Sognnaes [10] was then in charge of the oral pathology service and hold the position of dean of the Harvard School of Dental Medicine from 1952 to 1960.

In 1960, he arrived at UCLA to found a dental school of which he was the dean until he retired in 1968 [10,11].

However, Sognnaes continued his research as professor of anatomy and oral biology there. He acquired international fame in terms of identification in forensic odontology.

And yet, he was more famous for his relative observations on Georges Washington's braces. Indeed, Dr Sognnaes demonstrated that the first American president did not wear braces with wooden teeth.

He also identified Adolf Hitler's remains and those of his partner, Martin Bormann, from archives gathered by the Allies.

Soon, the preeminent researcher focused on the pathologies of hard tissues and on the calcifications in biological systems. His research allowed him to join a small circle of world specialists. He published more than 300 articles during his life. He was the first dentist to be elected member of the National Academy of Sciences, Institute of Medicine. He was honorary member in numerous international scientific societies and was also the chairman of the International Association for Dental Research, of the American Institute of Oral Biology and of the International Association for Identification in Forensic Odontology. A busy man, Reidar continued to work until he died of a heart attack on September 21, 1984 [10,11].

He made his dream come true by founding the dental school in UCLA which is of the highest importance within the UCLA Health Sciences Center.

It is also essential to mention Dr Michel Perrier's research works from the Institute of legal medicine in Switzerland that he made from propaganda films dating from 1934 and 1944 in which Hitler was seen smiling or making a speech. In his research, he drew a comparison between the images revealed by the reports and the Führer's dental archives. Helped with sophisticated film equipment, the analysis of those documents indisputably constituted an additional contribution to the German Chancellor's identification [9].

Who was Hugo Blashke (Fig. 5) ?

Hugo Blaschke [12] was born on November 14, 1881 in Neustadt, Prussia. He passed successfully his exam to become a dentist in the USA. From 1914 to 1918, he served during World War I as a country doctor. He received the War Merit Cross of 2nd class with Swords and the Honour Cross for combatants.

In 1931, Blaschke joined the National Socialist German Workers' Party under the number 452 082.

On March 1, 1931, he joined Röhm's SA. On May 2, 1935, he joined the SS led by Himmler as Major under the number 256 882. On July 1, 1935, he got married. On April 20, 1937, he was promoted to the rank of lieutenant colonel to Himmler's general staff. On April 20, 1939, he became Colonel at the SS headquarters. On January 1, 1941, he joined the Waffen-SS as Colonel and was also in charge of the Health Department. On April 20, 1941, he was promoted to the rank of Colonel-in-Chief in the General SS and more particularly, in the general staff of the General Staff service. On January 30, 1942, he was appointed Colonel-in-Chief in the Waffen-SS at the Health Department. On June 25, 1943, Hitler appointed him Honorary Professor. On October 1, 1944, he was promoted to the rank of Brigadier General in the General SS. On November 9, 1944, he was given the rank of Major-General of the Waffen-SS next to the doctor of the Reich SS and the Police.

Blaschke [13] organised and was also in charge of all the SS and the police dental department, and was Hitler, Himmler, Goering, Eva Braun's personal dentist let alone that of other important people. After the war, Blaschke was interned as prisoner in Nuremberg [14]. He was sentenced to 10 years of imprisonment for War Crimes and Crimes against Humanity. His involvement in the exploitation of dental gold extracted from dead prisoners' mouths in concentration camps was considered indisputable.

Fig. 1 - Fragment of Adolf Hitler's mandible [14].



Fig. 2 - Etchmann's sketch of Eva Braun's left side teeth [8]. To the left, the bridge that was never inserted.

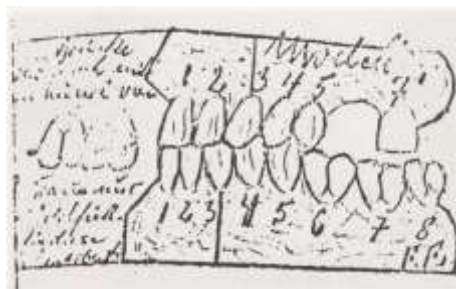


Fig. 3 - Echtmann's sketch of Eva Braun's upper jaw [8]. Teeth seen towards their chewing surfaces.



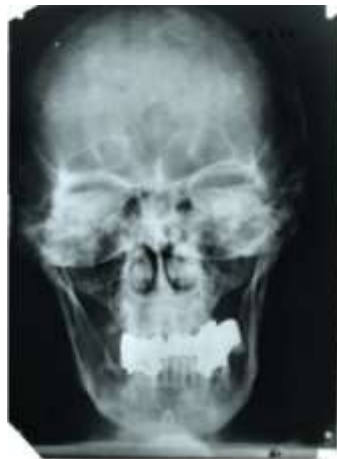
Fig. 4 - Dr Reidar F. Sognaes (1911-1984) [10,11].



Fig. 5 - Pr Hugo Blaschke (1881-1953) [15].



Fig. 6 - Adolf Hitler X-Rays (1944) [6].



REFERENCES

- American Board of Forensic Odontology (2006) Diplomates Reference Manual.
- Benecke Mark (2003) Hitler's skull and teeth in www.benecke.com 1-3.
- Benecke Mark (2003) Mein dentures: the hunt of Hitler's teeth in *Bizarre Magazine* 78: 51-53.
- Bundesarchiv Berlin (2004) Berlin, Allemagne.
- Feral Thierry, Le national-socialisme, vocabulaire et chronologie [National Socialism, vocabulary and chronology], L'Harmattan (éd.), Collection Allemagne d'hier et d'aujourd'hui [Yesterday and today's Germany Collection], Paris, 1998.
- Keiser-Nielsen S, Strøm F (1983) The odontological identification of Eva Braun Hitler. *Forensic Sci Int* 21: 59-64.
- Keiser-Nielsen Søren (1992) Teeth that told, University Press, Odense.
- Kirchhoff Wolfgang (Hrsg) (1987) Zahnmedizin und Faschismus, Verlag Arbeiterbewegung und Gesellschaftswissenschaft, Marburg.
- Lamendin Henri, Anecdodotes, Aventis (éd.), 2002.
- Perrier Michel (2000) Identification of A. Hitler from cinematographic documents, in Proceedings of the European IOFOS Millenium Meeting, Leuven University Press, Leuven 149-151.
- Riaud Xavier (2005) Les dentistes allemands sous le III^{ème} Reich [German dentists under the 3rd Reich], L'Harmattan (éd.), Collection Allemagne d'hier et d'aujourd'hui [Yesterday and today's Germany Collection], Paris.
- Riaud Xavier, Les dentistes, détectives de l'Histoire [Dental detectives of history], L'Harmattan (éd.), Collection Médecine à travers les siècles [Medicine throughout the centuries Collection], Paris.
- Schulz Wilhelm (1989) Zur Organisation und Durchführung der zahnmedizinischen Versorgung durch die Waffen-SS in den Konzentrationslagern während der Zeit des Nationalsozialismus, Bonn, Dissertation.
- Sognaes Reidun (2006) Half Moon Bay, CA, USA.
- Sognaes RF, Strøm F (1973) The odontological identification of Adolf Hitler. Definitive documentation by X-Rays, interrogation and autopsy findings. In *Acta Odont Scand* 31: 43-69.
- Stephenson David (2003) Discovering the truth, the whole tooth about Hitler's death. In *Daily Express*, London 54-55.