

CYTOARCHITECTURAL DISTORTION OF THE LIVER FOLLOWING THE ADMINISTRATION OF AQUEOUS MORINGA OLEIFERA SEED ON ACETAMINOPHEN INDUCED HEPATOTOXICITY IN WISTAR RATS.

Inyang, Imeobong J., Fischer, Victor A., Eru, Eru M., Uruakpa, Kelechi C.

Department of Human Anatomy,
Faculty of Basic Medical Sciences,
University of Calabar-Nigeria.

ABSTRACT: *This study aimed at elucidating the effects of moringa oleifera seed on acetaminophen (paracetamol) induced hepatotoxicity in wistar rats. Thirty two adult wistar rats were distributed into four treatment groups of eight animals each. Group A received normal chow and distil water, group B received 600mg/kg of moringa oleifera, group C received 6g/kg of paracetamol, group d received 600mg/kg of moringa oleifera and 6g/kg of acetaminophen for ten days. Twenty four hours after the last administration, the experimental animals were sacrificed, the liver was removed and fixed in 10% formal saline. After complete fixation, the tissues were processed and stained with haematoxylin and eosin. Under the light microscope, the histological examination of the liver showed marked tissue changes characterised by marke mononuclear cell infiltration, peripheral fibrosis, scattered limiting plate and dilated sinusoidal spaces in group D. this finding showed that moringa oleifera seed though containing natural antioxidant did not confer hepatoprotective effects on the liver architecture.*

KEYWORDS: moringa oleifera seed, liver, wistar rat, cytoarchitectural distortion

INTRODUCTION

Moringa oleifera is widely distributed in the world especially in Asian countries and is a highly cultivated and valued plant in tropical and subtropical countries (Khalifalla et al 2010). moringa oleifera's root, stern bark, gum, seed, flowers, and leaf has wide medicinal properties for the treatment of disease such cardiovascular diseases; the various part contain nitrile, mustard oil glycosides, and thiocarbamate glycosides as their important bioactive constituents thought to be responsible for their diurectic, cholesterol lowering, and antiulcer properties (Anwar et al 2007). Some studies showed strong in vitro antioxidant properties of the methanolic extract of moringa oleifera edible parts which is due to the presence of various bioactive compouds such as chlorogenic acid, rutin, quercetin glucoside, and kaempferol rhamnoglucoside (Atawodi et al 2010). the extract also has potent antioxidant action in vivo (Ashok et al 2003; Arabshahi et al 2007; Verma et al 2009;& Sreelatha 2011), the leaves contain protein, β -carotene, vitamins A, B, C and E, riboflavin, nicotinic acid, folic acid, pyridoxine, amino acids, minerals and various phenolic compounds (Khalafalla et at 2010 & Anwar et al 2007). The flower has hepatoprotective effects due to the presence of major amounts of the bioactive compound quercetin (Bharali et al 2003). Seeds are used as a biosorbent for the removal of cadmium from aqueous medium and are one of the best-known natural coagulants discovered so far from natural sources (Ghebremichael et al 2005), they have antipyretic, acrid, and also antimicrobial activities (Oliveira et al 1999). Sharida and co-workers (2012) suggested that moringa oleifera leave and flowers hydroethanolic extract showed a significant reduction in the severity of the

liver damage after using acetaminophen to induce hepatotoxicity in rats and concluded that moringa oleifera has a potential role in therapeutic action by altering oxidative stress due to the presence of phenolic compounds and its antioxidant nature. Eswar et al 2013 evaluated in vitro antioxidant and in vivo hepatoprotective activity of moringa oleifera seeds extract against ethanol induced liver damage using wistar rats and concluded that ethanolic extract of moringa oleifera seeds has significant antioxidant and hepatoprotective activity against ethanol induced hepatotoxicity; and this activity is associated with high content of bioactive compounds such as glucosinolates, isothiocyanates, thiocarbamates and flavonoids and antioxidant properties. Paul & Didia (2012) suggested that methanolic extract of moringa oleifera lam roots distort liver and kidney's histoarchitecture of the guinea pigs and also the effects are dose and duration dependent. In 2012, Saalu and coworkers administered moringa oleifera leaf extract on alcohol-induced hepatotoxicity in wistar rats and suggested that the moringa oleifera leaf extract reduces the hepatotoxicity caused by alcohol ingestion and concluded that moringa oleifera protects animal against alcohol-induced liver oxidative damage. Buraimoh and co-workers observed hepatoprotective effect of ethanolic leave extract of moringa oleifera on the histology of paracetamol induced liver damage in wistar rats. They suggested that the necrotic hepatic cells caused by paracetamol ingestion were reduced drastically following post administration of moringa oleifera leaf extract in 2011. Ajilore and co-workers in 2012 studied the protective effect of moringa oleifera lam. on cadmium-induced liver and kidney damage in male wistar rats and found out that the extract administered ameliorated the toxic effect caused by cadmium ingestion. In 2014, Olatosin experimental team mates observed the effects of moringa oleifera seed oil on acetaminophen-induced oxidative stress and liver damage in wistar rats showing reduction in the severity of the liver injury with significantly lowered ($p < 0.05$) hepatic melondialdehyde formation.

The liver is the largest abdominal viscera occupying a substantial portion of the upper abdominal cavity. It is reddish brown in colour and possesses four lobes (right, left, quadrate and caudate). Embryologically, the liver is an epithelial-mesenchymal outgrowth of caudal part of the foregut. It consist of a complex network of epithelial cells supported by connective tissue and perfused by blood vessels from hepatic portal vein and artery. The epithelial cells (hepatocytes) carry out the major metabolic activities; other cell types possess storage, phagocytic and mechanically supportive functions such as hepatic stellate cells, sinusoidal endothelial cells and kupffer cells (Henry & Carter 2008).

MATERIALS AND METHODS

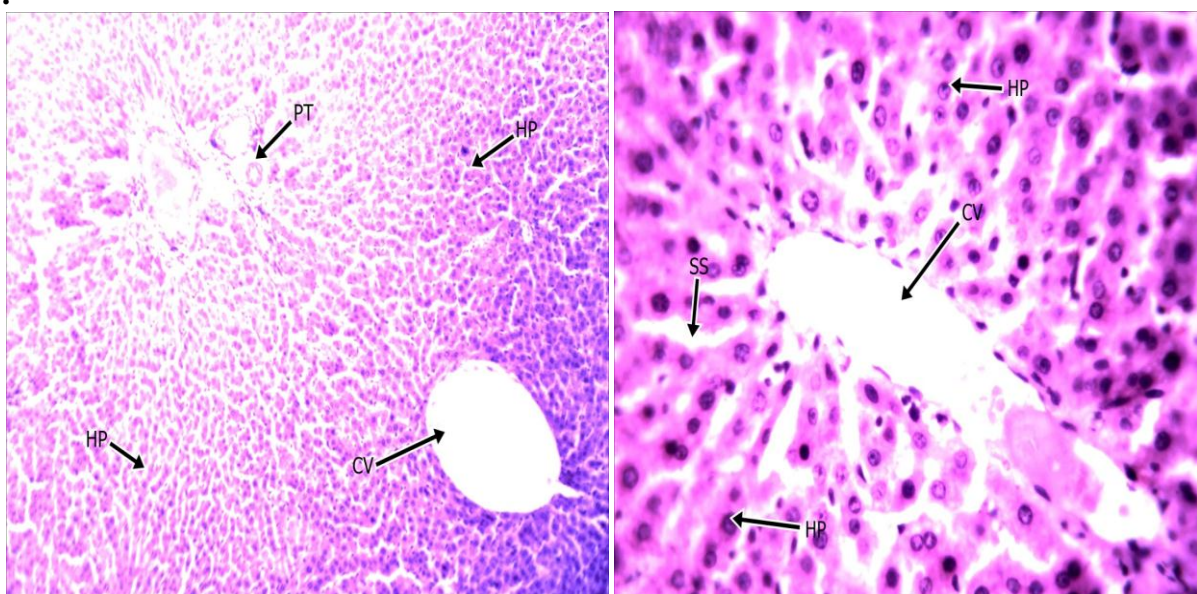
Thirty two adult wistar rats weighing 190-200g were randomly separated into four groups designated A, B, C, and D each containing eight rats. The control groups A and received chow and distil water. Group B received 600mg/kg, group C received 6g/kg of acetaminophen and group D received 600mg/kg of aqueous moringa oleifera and 6g/kg of acetaminophen for ten days. Twenty four hours after the last administration, the experimental animals were sacrificed and the liver tissues removed and fixed in 10% formal saline. Following complete fixation of the liver, routine histological technique was carried out. Sections of the liver were stained with haematoxylin and eosin and viewed under light microscope.

RESULT

After routine tissue processing, the result under light microscope showed preserved cytoarchitecture of the liver with prominent central veins and hepatocytes radiating outward.

The portal triad and the limiting plates are intact in the control group. Group B treated with *Moringa oleifera* only showed preserved cytoarchitecture with prominent bile duct, radiating hepatocytes, portal vein, round to oval basophilic nuclei and eosinophilic cytoplasm. Group C section treated with acetaminophen showed expanded portal triad with marked mononuclear inflammatory and periportal fibrosis. The limiting plate are scattered, the sinusoidal spaces are heavily dilated and contain heavily dilated mononuclear infiltrates as well as patchy hydropic changes within the hepatocytes. Group D treated with *Moringa oleifera* and acetaminophen showed marked portal inflammation mainly mononuclear infiltrations with total destruction of the limiting plates and dilated sinusoidal spaces. The hepatocytes are prominent with moderate eosinophilic cytoplasm, round to oval basophilic nuclei having prominent nuclei and congested central veins.

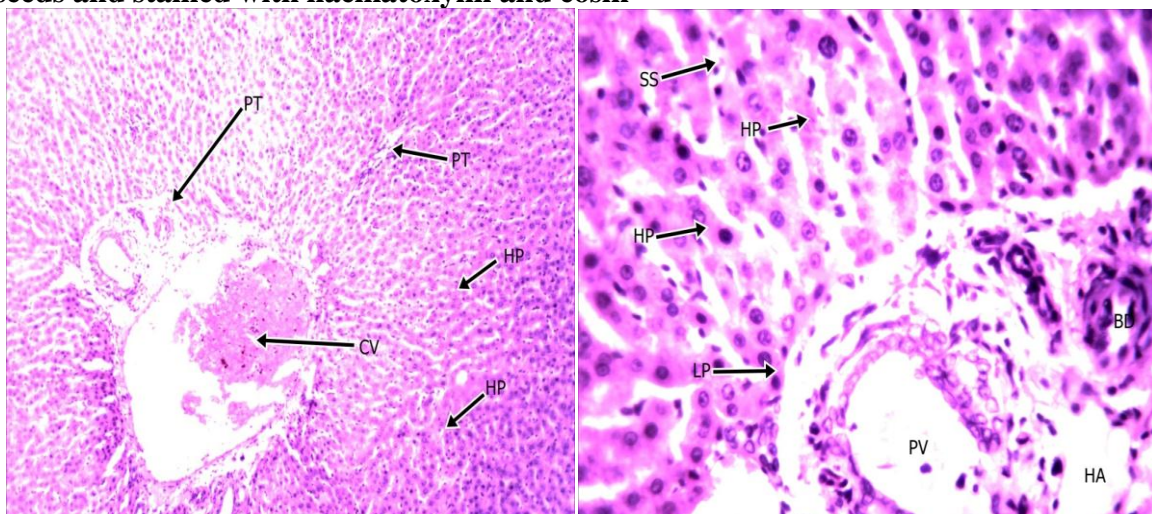
Plate I : Photomicrograph of normal control group stained with haematoxylin and eosin



x100

x 400

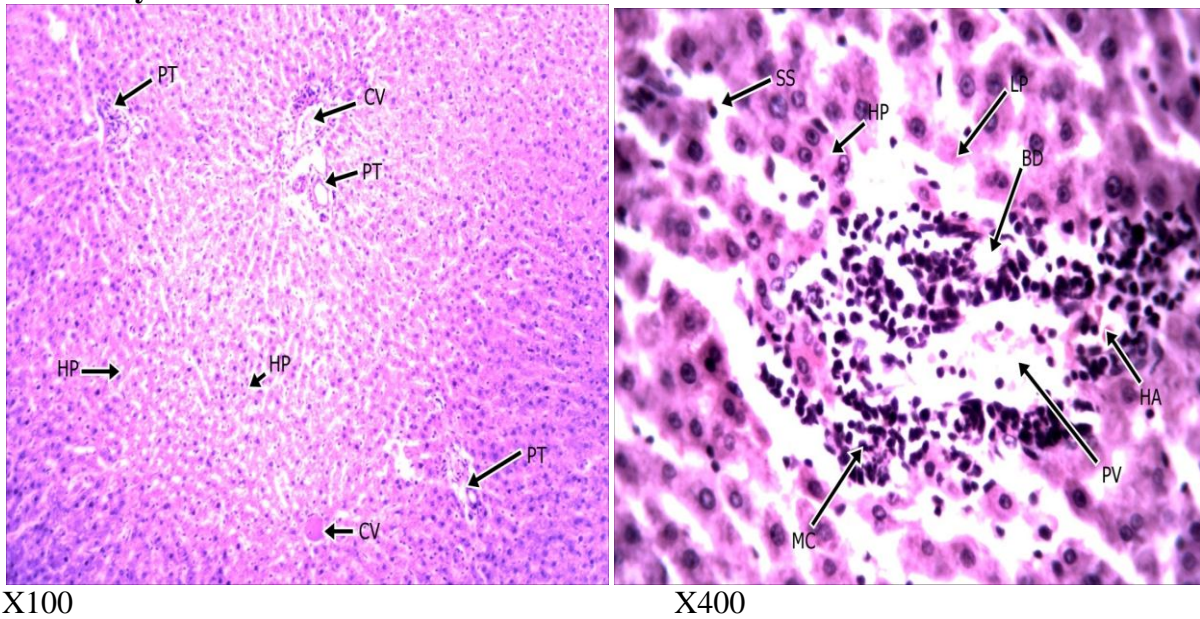
Plate II: Photomicrograph of liver of albino wistar rats treated with *Moringa oleifera* seeds and stained with haematoxylin and eosin



x100

x400

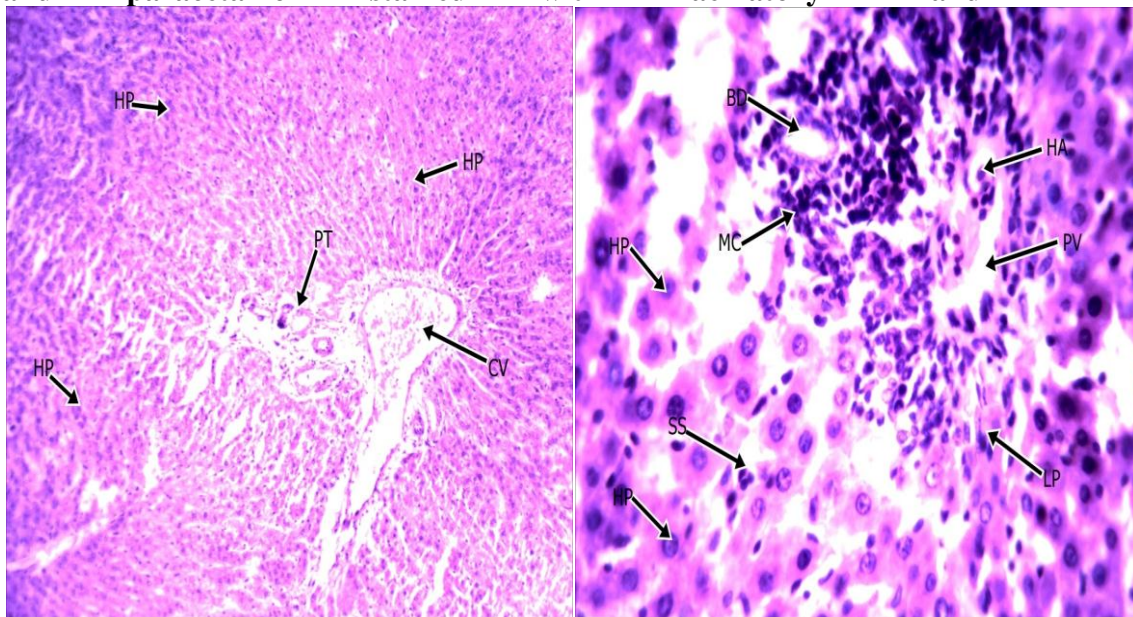
Plate III: photomicrograph of liver treated with acetaminophen and stained with haematoxylin and eosin.



X100

X400

Plate IV : photomicrograph of liver of albino wistar rats treated with moringa oleifera and paracetamol stained with haematoxylin and eosin.



X100

X400

DISCUSSION

Moringa oleifera is widely distributed in the world especially in Asian countries and is a highly cultivated and valued plant in tropical and subtropical countries (Khalifalla et al 2010). moringa oleifera's root, stem bark, gum, seed, flowers, and leaf has wide medicinal properties for the treatment of disease such as cardiovascular diseases; the various part contain nitrile, mustard oil glycosides, and thiocarbamate glycosides as their important bioactive constituents thought to be responsible for their diurectic, cholesterol lowering, and antiulcer properties (Anwar et al 2007). In this study moringa oleifera seed extract was used to ascertain the level of

hepatoprotective effect on the cytoarchitecture of the liver. Thirty two adult wistar rats were used to investigate its effect on the liver architecture. Group A served as control and received distilled water, group B was given 600mg/kg of moringa oleifera seed extract, group C was given 60g/kg of acetaminophen and group D was given 6g/kg of acetaminophen and 600mg/kg of moringa oleifera seed extract. Twenty four hours after the last administration, the experimental animals were sacrificed and the tissue sections were fixed in formal saline. Following fixation the tissues were processed using routine histological technique.

With the aid of a light microscope, sections showed visible alteration to the histological architecture of liver of the experimental rats after administration of paracetamol at 6g/kg hepatotoxic dose and 600mg/kg of *Moringa oleifera* seeds for 10 days. Stained sections of liver from the control and treated animals were generally analyzed as follows. The control section of the liver showed a preserved architecture with prominent central vein (cv) and radiating plates of hepatocytes (HP). The hepatocyte shows prominent eosinophilic cytoplasm and round to oval basophilic nuclei. Sinusoidal spaces (ss) are dilated. The portal tracts and limiting plates (LP) are intact (plate I). The liver of *Moringa* only treatment group (group B) showed a preserved architecture after treatment with prominent bile duct (BD) and radiating hepatocytes and prominent portal vein and round to oval basophilic nuclei and eosinophilic cytoplasm (plate II). The liver of paracetamol treatment group (Group C) showed expanded portal tracts with marked mononuclear inflammatory cells (MC) and periportal fibrosis. The limiting plates (LP) are scattered. The sinusoidal spaces are heavily dilated and contain mononuclear infiltrates. There are patchy hydropic changes within the hepatocytes indicated by swollen hepatocytes or clearing (Plate III). The *Moringa* and paracetamol treated group (group D) sections showed a marked portal inflammatory mainly mononuclear infiltrates with focal destruction of the limiting plate and dilated sinusoidal spaces (ss). The hepatocytes are prominent with moderate eosinophilic cytoplasm and round to oval basophilic nuclei having prominent nuclei. Central vein (cv) are congested (plate IV). *Moringa oleifera* has been shown to have hepatoprotective effects when administered to experimental animals such as wistar albino rats (Bhatnagar and Krishna, 2013). In this study, it showed that there was no hepatoprotective effects in contrast to the conclusion of Buraimoh *et al.*, 2010, who had concluded that one of the antioxidant contained in *Moringa* seed is glutathione but glutathione according to (Roderick and Whaley, 1997) is required in the pathway of paracetamol metabolism to conjugate the reactive NAPQI to prevent it from causing liver damage so its either the amount of the antioxidant present in the seed is not enough or is inactive. Furthermore, in a study by Olatosin *et al.*, 2014, *Moringa oleifera* seed oil was found to be hepatoprotective in acetaminophen (paracetamol) induced hepatotoxicity and this was because in the process of extracting the *Moringa oleifera* seed oil, the active antioxidants are activated (Misra, 1972) by converting the superoxide anion in the binding site to superoxide dismutase thus allowing it to bind to the active NAPQI from paracetamol metabolism. Therefore according to the above study, the seeds in its natural state have not conferred hepatoprotective action as shown in this study except when used as seed oil.

REFERENCES

- A.A. Buraimoh, I.G. Bako & F.B. Ibrahim (2011). Hepatoprotective Effect of Ethanolic Leave Extract of *Moringa oleifera* on the Histology of Paracetamol Induced Liver Damage in Wistar Rats. *International Journal of Animal and Veterinary Advances*: 3.1: p. 10-13
- Ajilore, B.S., Atere, T.G., Oluogun, W.A. and Aderemi, V.A. (2012). Protective Effects of *Moringa oleifera* Lam. on Cadmium-induced Liver and Kidney Damage in Male Wistar Rats. *International Journal of Phytotherapy research*. 2:3. P. 42-50.
- Anwar, F.; Latif, S.; Ashraf, M.; Gilani, A.H. *Moringa oleifera*: A food plant with multiple medicinal uses. *Phytother. Res.* 2007, 21, 17–25.
- Khalafalla, M.M.; Abdellatef, E.; Dafalla, H.M.; Nassrallah, A.A.; Aboul-Enein K.M.; Lightfoot, D.A.; El-Deeb, F.E.; El-Shemy, H.A. Active principle from *Moringa oleifera* Lam leaves effective against two leukemias and a hepatocarcinoma. *Afr. J. Biotechnol.* 2010, 9, 8467–8471.
- Atawodi, S.E.; Atawodi, J.C.; Idakwo, G.A.; Pfundstein, B.; Haubner, R.; Wurtele, G.; Bartsch, H.; Owen, R.W. Evaluation of the polyphenol content and antioxidant properties of methanol extracts of the leaves, stem, and root barks of *Moringa oleifera* Lam. *J. Med. Food* 2010, 13, 710–716.
- Ashok Kumar, N.; Pari, L. Antioxidant action of *Moringa oleifera* Lam. (drumstick) against antitubercular drugs induced lipid peroxidation in rats. *J. Med. Food* 2003, 6, 255–259.
- Arabshahi, D.S.; Devi, V.; Urooj, A. Evaluation of antioxidant activity of some plant extracts and their heat, pH and storage stability. *Food Chem.* 2007, 100, 1100–1105.
- Verma, A.R.; Vijayakumar, M.; Mathela, C.S.; Rao, C.V. In vitro and in vivo antioxidant properties of different fractions of *Moringa oleifera* leaves. *Food Chem. Toxicol.* 2009, 47, 2196–2201.
- Sreelatha, S.; Padma, P.R. Modulatory effects of *Moringa oleifera* extracts against hydrogen peroxide-induced cytotoxicity and oxidative damage. *Hum. Exp. Toxicol.* 2011, 30, 1359–1368.
- Ghebremichael, K.A.; Gunaratna, K.R.; Henriksson, H.; Brumer, H.; Dalhammar, G. A simple purification and activity assay of the coagulant protein from *Moringa oleifera* seed. *Water Res.* 2005, 39, 2338–2344.
- Oliveira, J.T.; Silveira, S.B.; Vasconcelos, I.M.; Cavada, B.S.; Moreira, R.A. Compositional and nutritional attributes of seeds from the multiple purpose tree *Moringa oleifera* Lamarck. *J. Sci. Food Agric.* 1999, 79, 815–820.
- Bharali, R.; Tabassum, J.; Azad, M.R. Chemomodulatory effect of *Moringa oleifera*, Lam, on hepatic carcinogen metabolising enzymes, antioxidant parameters and skin papillomagenesis in mice. *Asian Pac. J. Cancer Prev.* 2003, 4, 131–139.
- Sharida Fakurazi 1, Syazana Akmal Sharifudin & Palanisamy Arulselvan (2012). *Moringa oleifera* Hydroethanolic Extracts Effectively Alleviate Acetaminophen-Induced Hepatotoxicity in Experimental Rats through Their Antioxidant Nature. *Molecules*. 17: p. 8334-8350
- Eswar Kumar K, Harsha K N, Shabana Shaik, Neelakanta Rao N, Giri Babu N, (2013). Evaluation Of In Vitro Antioxidant Activity and In Vivo Hepatoprotective Activity Of *Moringa Oleifera* Seeds Extract Against Ethanol Induced Liver Damage In Wistar Rats. *IOSR Journal of Pharmacy*.3:1. P. 10-15.

- Olatosin T. M., Akinduko D. S., Uche C. Z., Bardi J. (2014). Effects of Moringa oleifera Seed Oil on Acetaminophen-Induced Oxidative Stress and Liver Damage in Wistar Albino Rats. *IOSR Journal of Pharmacy and Biological Sciences (IOSR-JPBS)*. 9:2. P. 53-59.
- C.W. Paul and B.C. Didia (2012). The Effect of Methanolic Extract of Moringa oleifera Lam Roots on the Histology of Kidney and Liver of Guinea Pigs. *Asian Journal of Medical Sciences* 4(1): p. 55-60.
- Misra, H. P., & Pridovich I. (1972). The role of superoxide anion in auto oxidation of tocopherol, *Journal of biology and chemistry* 24:712-715
- Roderrick M & Keith whaley (1997). Drug and radiation induced injury. *Muir's pathology*. Glasgow, London, 41-43.
- Bhatnagar, A., & Krishna, A. G. (2013). Natural antioxidants of *Moringa oleifera* seed oil as compared to other vegetables oil. *Tree of life Journal*.(12) (5) :537-540
- Saalu, L.C., Ogunlade, B., Ajayi, G.O., Oyewopo, A.O., Akunna, G.G., Ogunmodede, O.S. (2012). The hepato-protective potentials of Moringa oleifera leaf extract on alcohol-induced hepato-toxicity in wistar rat. *African Journal Biotechnology and Molecular sciences*: 2.1: P 6-14.
- Henry Gray & Susan Standring (2008). *Anatomy: the anatomical basis of clinical practice* (40th ed). Churchill livingstone Elsevier. Pp 1163-1175.

Abbreviation: MO= moringa oleifera, NAPQI= N-acetyl-P-Benzoquinone